

CASE REPORT

A large hematometra after cervical carcinoma in situ - a case report and review of literature

Zeba Khanam, Roli Purwar, Ankita Kumari

Corresponding author: Dr Zeba Khanam, Assistant Divisional Medical Officer and Consultant Gynaecologist, Department of Obstetrics and Gynaecology, Central Hospital, Northern Railways, Gorakhpur, India; Email : drzebakhanam@gmail.com

Distributed under Attribution-Non Commercial – Share Alike 4.0 International (CC BY-NC-SA 4.0)

ABSTRACT

The association of a pre-invasive cervical lesion with hematometra is uncommon except in cases where the former is associated with a uterine malignancy. To date, an isolated cervical preinvasive lesion (without a concomitant endometrial involvement) leading to hematometra has not been reported. We report here such a unique case and provide useful insights and highlight learning points in its management along with a brief review of literature.

A postmenopausal female presented with a huge abdominopelvic mass which was later reported as a hematometra. The underlying carcinoma-in-situ of the cervix had lead to cervical stenosis. Accompanying endometritis culminated in the collection of a massive amount of blood inside the endometrial cavity.

Keywords: Abdominopelvic mass, postmenopausal bleeding, uterine neoplasia, hematometra.

Menopause is a point in time that follows one year after the complete cessation of menstruation. Postmenopause describes years following that point. Postmenopausal bleeding is defined as vaginal bleeding occurring postmenopause. Its presentation as hematometra is a rare phenomenon. The most common cause of postmenopausal hematometra is cervical stenosis secondary to senile atrophy of the cervix. Although carcinoma in situ cervix (CIC) can lead to cervical stenosis in 12% of cases, its association with hematometra without an associated uterine neoplasia is exceedingly rare¹. We report here management of such a case of a postmenopausal hematometra which had developed secondary to cervical stenosis after CIC.

Case

A 70 year old postmenopausal multipara presented with complaints of mass and vague pain in the lower abdomen for one year. On examination, there was a midline, well defined, mobile, non-tender abdominopelvic mass with cystic-solid consistency and corresponding to the size of a 28 weeks sized gravid uterus. Cervical motion was transmitted to the

mass on per vaginum examination. Ultrasound reported a septated ovarian mass in the pelvis, extending posteriorly to an enlarged uterus. On contrast enhanced computed tomography (CECT), a bilateral cystic space occupying lesion was noted. The one occupying left side and to the midline of the pelvis was a large 14x11cm², thick walled high density lesion. The other on the right and in pouch of Douglas was 11x6 cm² low density multiseptated cystic lesion with enhancing septa (figure - 1a,1b). No gross pelvic or retroperitoneal lymphadenopathy was noted. A provisional diagnosis of a benign ovarian mass with hematometra was made. A staging laparotomy was planned.

An extrafascial hysterectomy with bilateral salpingo-oophorectomy and pelvic lymph node dissection was done. Intraoperatively, uterus was enlarged with collected blood. A cystic multilobulated mass was found arising from the right ovary and impacted in the pouch of Douglas (figure 2).

Histopathological evaluation revealed senile chronic endometritis without features of atypia or invasion. Cervix revealed squamous cell carcinoma in situ. Complete cervical

Received: 26th June 2021, Peer review completed: 28th September 2021, Accepted: 10th June 2021.

Khanam Z, Purwar R, Kumari A. A large hematometra after cervical carcinoma in situ - a case report and review of literature. The New Indian Journal of OBGYN. 2023; 10(1): 225-28.

stenosis was noted. There was a 7x5x4 cm³ benign right ovarian serous cystadenoma. The right external iliac lymph node showed reactive lymphoid hyperplasia. Bilateral tubes and ovaries were unremarkable. The patient was discharged on postoperative day eight of surgery in stable condition.

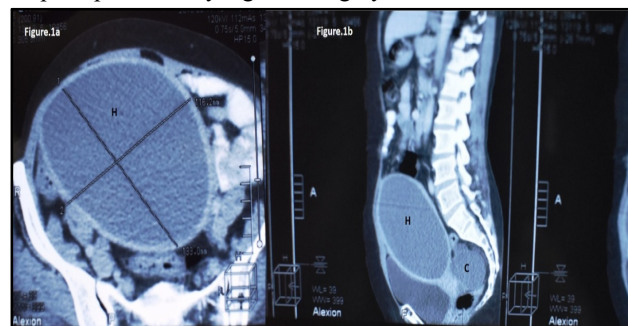


Figure1: Axial (1a) and sagittal (1b) CECT views; (H= Hematometra, C= Ovarian Cyst)

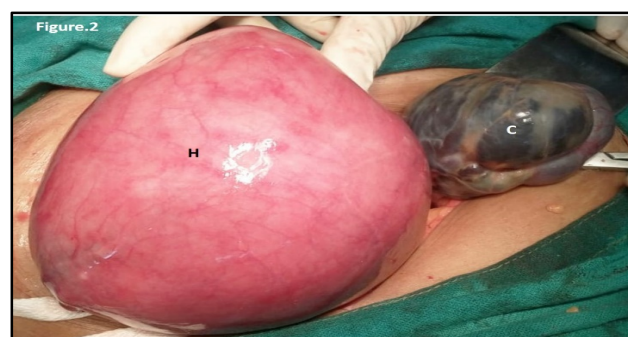

Figure 2: A huge hematometra with right serous cystadenoma

Discussion

Hemometra or hematometra is a rare gynaecological condition with an accumulation or retention of blood in the body of the uterus secondary to a congenital or acquired structural obstruction of the outflow female genital tract. The former accounts for the majority number of cases ². Congenital defects like an imperforate hymen, transverse vaginal septum, and vaginal hypoplasia present with dysmenorrhea, cyclical cramping pelvic pain, foul smelling vaginal discharge, and abdominopelvic mass 1-2 years after the onset of menarche. In extremes of cases, the underlying hematometra can lead to pelvic endometriosis or a tubo-ovarian abscess. Acquired hematometra, on the other hand, is mostly iatrogenic and almost always after cervical canal obstruction. Conisation and hysteroscopic trans cervical resection of the endometrium are notable causes where complete cervical stenosis can present with this rare,

although very serious complication in menstruating females. The incidence of hematometra after cervical conisation is reported to be less than 1%.

Worldwide, the average age of onset of menopause is considered to be 51.5 years ³. Bleeding per vaginum after menopause is seen in 5% of all gynaecological cases ⁴. The most common cause of postmenopausal bleeding in the absence of hormone replacement therapy is senile endometrial atrophy. The most important cause, on the other hand, is a genital malignancy and notably endometrial carcinoma. Burbos et al have documented that vaginal bleeding occurs in 90% of women with endometrial cancer and in 10% (1–25%) of women who present with postmenopausal bleeding there is an underlying endometrial carcinoma ⁵.

The finding of postmenopausal hematometra is exceedingly rare in gynaecological practice (1:10000 gynaecologic hospital admissions). It is almost always secondary to cervical canal obstruction. Contraction of cervical scar tissue or agglutination of endocervix can occasionally occur after senile cervical atrophy, pelvic irradiation, or in women with a history of chronic cervicitis. In the setting of cervical stenosis, endometrial secretions and cellular debris get trapped into the uterine cavity and accumulate as hematometra. It can later become infected and form a pyometra. Endometrial or cervical cancer outgrowths may also directly lead to a pyometra when they obstruct the endocervical canal ². Hematometra when associated with endometrial carcinoma and presents late in the course of the disease, carries a dismal prognosis.

Carcinoma cervix presents with postmenopausal bleeding in less than 10% cases ⁶. The most common presenting complaints are copious foul smelling vaginal discharge, abnormal vaginal bleeding or intermenstrual bleeding, postcoital bleeding, and backache. Without an associated extension to the uterus, cervical carcinoma per se do not lead to an endometrial bleed. To date, only 34 cases of squamous cell carcinoma of cervix extending to uterus have been reported. Out of them, only two cases were associated with hematometra ⁷.

Cervical preinvasive lesions, namely cervical intraepithelial neoplasia (CIN) and CIC are usually asymptomatic in majority of cases. The literature on an association of preinvasive cervical lesion with hematometra is relatively scarce. In a single study to date, Agashe et al have reported a CIC with secondaries in the uterus leading to a hematometra ⁸. Nowhere in literature, we could find an

association between a hematometra and an isolated CIC i.e. without a concomitant uterine involvement. However, Newman and Finan had reported that CIC can lead to cervical stenosis in 12% of cases¹. This, in turn, can lead to hematometra in the setting of an endometritis as in our case.

Transvaginal sonography (TVS) is considered superior to transabdominal sonography (TAS) in detecting the majority of pelvic masses. CT is considered less helpful in investigating the abnormalities within the uterus. Where available, Magnetic resonance imaging (MRI) is the imaging modality of choice for the anatomical study of the pelvis and abdomen. Liu et al have demonstrated that the diagnostic accuracy of combined CT scans and ultrasound for pelvic masses was far superior to either test alone⁹. The sensitivity, specificity, and accuracy of combined application of ultrasound and CT were 89%, 94.7%, and 91.7% respectively. On the contrary, Khan et al reported that transvaginal sonography had the highest overall accuracy for diagnosing pelvic masses with CT having the least accuracy (63%) for benign uterine lesions¹⁰.

Endometrium and cervix should be promptly assessed in all cases of postmenopausal hematometra. Endocervical curettage is a must. It should be followed by dilation of the endocervical canal and curettage of the endometrial cavity in the same setting. Further management should be guided by the histopathological analysis. 60% of complex endometrial hyperplasias and 11% of endometrial cancers may be missed by dilation and curettage (D&C) as most pathological lesions have a focal growth pattern and in D&C less than half of the endometrial cavity is curetted. Hysteroscopy and guided biopsy is hence regarded as the gold standard investigation for postmenopausal bleeding and is advised where histopathological reports are not conclusive. If the cause of bleed remains obscure even after hysteroscopy and guided biopsy, hysterectomy is the mainstay of treatment². In our case, hematometra was formed due to the accumulation of endometrial bleed from senile endometritis which could not escape the uterine cavity because of cervical stenosis.

Treatment options for CIC include conisation, LEEP (Loop Electrosurgical Excision Procedure)/LLETZ (Large Loop Excision of the Transformation Zone), or an extra fascial hysterectomy. The concomitant presence of a large para-ovarian mass justified an extra fascial hysterectomy with bilateral salpingo-oophorectomy in our case. Regular follow up with Papanicolaou smear of the vault is considered adequate in such cases.

Conclusion

A holistic approach is required for the management of a case of postmenopausal abdominopelvic mass. TVS should be the first line investigation followed by a CT or an MRI. In all cases of postmenopausal hematometra cervical and uterine malignancy should be positively ruled out.

Learning points -

- TVS should be the first line of investigation in cases of postmenopausal abdominopelvic mass. An MRI pelvis or CT scan can be further advised. A senior radiologist should be involved in reporting of such cases at all times. Further, a senior gynaecologist should also be involved in the management of such cases.
- Preoperative cytological evaluation of the cervix should be done in all cases of postmenopausal abdominopelvic mass.

Finding of postmenopausal hematometra should arouse suspicion of endometrial or cervical malignancy. A holistic and thorough approach is advised in the management of such cases.

Conflict of interest: None. **Disclaimer:** Nil.

References

1. Newman C, Finan MA. Hysterectomy in women with cervical stenosis: Surgical indications and pathology. *Journal of Reproductive Medicine for the Obstetrician and Gynecologist*. 2003; 48(9): 672-76.
2. Güven S, IlicaAT, Yilmaz A, Alanbay I. A Case of Asymptomatic Postmenopausal Hematometra Mimicking Endometrial Carcinoma. *Gynecology Obstetrics & Reproductive Medicine*. 2007;13(1):67-9.
3. Bradshaw KD. Menopausal Transition. In: Hoffman BL, et al., editors. *Williams Gynaecology*. 2nd ed. New York: McGraw-Hill Medical; 2012. p. 554.
4. Moodley M, Roberts C. Clinical pathway for the evaluation of postmenopausal bleeding with an emphasis on endometrial cancer detection. *Journal of Obstetrics and Gynaecology*. 2004; 24(7): 736-41.
5. Burbos N, Musonda P, Giarenis I, Shiner A, Giamougiannis P, Morris E, et al. Predicting the risk of endometrial cancer in postmenopausal women presenting with vaginal bleeding: the Norwich DEFAB risk assessment tool. *British Journal of Cancer*. 2010; 102(8):1201-6.

6. Kim MK, Jung YS, Chon SJ, Yun BH, Cho S, Choi YS, et al. Common Causes of Postmenopausal Bleeding in Korean Women: 10-Year Outcomes from a Single Medical Center. *J Korean Med Sci.* 2017 May; 32(5): 830-34.
7. Kumari G, Tempe A, Verma N, Singh N. Gynaecology Carcinoma Cervix Presenting as Predominant lesion of Uterine Corpus: Posing Diagnostic & Management Dilemma. *Indian journal of Applied Research.* 2007; 7(6): 6-7.
8. Agashe SR, Kulkarni MP, Momin YA, Sulhyan KR. Superficial extension of squamous cell carcinoma in situ of cervix involving endometrium, bilateral fallopian tubes and ovaries: a case report. *Indian journal of pathology & microbiology.* 2007; 50(2): 375-77.
9. Liu Y, Zhang H, Li X, Qi G. Combined Application of Ultrasound and CT Increased Diagnostic Value in Female Patients with Pelvic Masses. *Computational and Mathematical Methods in Medicine.* 2016; 2016:1-5.
10. Khan S, Gupta K, Singh P. Comparing Diagnostic Accuracy of Ultrasound and CT in Diagnosing Pelvic Masses. *Ann Int Med Den Res.* 2020; 6(2):OG05-OG08.

Zeba Khanam ¹, Roli Purwar ², Ankita Kumari ³

¹ Assistant Divisional Medical Officer and Consultant Gynaecologist, Department of Obstetrics and Gynaecology, Central Hospital, Northern Railways, Gorakhpur, India; ² Senior Resident, Department of Obstetrics and Gynaecology, All India Institute of Medical Sciences, New Delhi, India; ³ Post-graduate resident, Department of Obstetrics and Gynaecology, Vardhman Mahavir Medical College and Safdarjung Hospital, New Delhi, India.