

RESEARCH ARTICLE

Histopathological examination of the placenta in normal and SGA pregnancy and its association with neonatal outcome

Erum Sajid, Indrani Ganguli, Sunita Bhalla, Mala Srivastava, Mamta Dagar

Corresponding author: Dr Erum Sajid, DNB student, Department of Obstetrics and Gynecology, Sir Ganga Ram Hospital, New Delhi, India; Email: erumhaz14@gmail.com

Distributed under Attribution-Non Commercial – Share Alike 4.0 International (CC BY-NC-SA 4.0)

ABSTRACT

Objective: To study histopathological characteristics of the placenta in SGA pregnancies and to associate it with neonatal outcomes. **Material and methods:** A total of 200 placentae were examined. 100 from the study group (SGA pregnancies) and 100 from the low-risk control group. After delivery, they were examined for any gross lesions and weighed. They were then sent for histopathological analysis. The results were then tabulated and compared between the two groups (study and control). **Results:** On studying the histopathology of the placenta we found abnormalities in 73 % of placentae in the study group as compared to 34% in the control group showing a significant association of placental pathology with FGR ($p < 0.05$). Salient histopathological findings in the study group were villous infarcts (52%), fetal thrombotic arteriopathy (11%), chronic villitis (7%), perivillous fibrin deposit (49%), decreased vascularity (45%), diffuse calcification (35%), syncytial knots (38%). We found that 82% of neonates were delivered before 37 completed weeks in the study group which was a significant finding ($p < 0.01$). The finding of 72% of neonates in the study group with birth weight < 2 kg was expected due to FGR babies. This finding was statistically significant. Our study failed to demonstrate any significant relation between major placental lesions and depression of APGAR score except for perivillous fibrin deposition which showed significant relation ($p < 0.05$). On comparing the placental lesions with decreased fetal weight (< 1.5 kg) we found decreased vascularity ($p < 0.05$) closely related to decreased fetal weight ($p < 0.05$). The other lesions failed to show any significant relationship between the two (chi-square two-tailed test). **Conclusion:** We found that though SGA fetuses are more commonly associated with histological placental abnormalities, it cannot be established whether these abnormalities certainly contribute to FGR. Malperfusion lesions of the placenta show a close association with not only FGR but decreased fetal weight and poor neonatal outcomes. We also found the association of perivillous fibrin and decreased vascularity significantly related to adverse neonatal outcomes.

Keywords: Small for gestational age, placenta, histopathology, neonatal outcome, fetal vascular malperfusion, perivillous fibrin deposition.

The term small for gestational age (SGA) is used for a fetus with a birth weight < 10 th customized percentile or less than 2 standard deviations for that population reference, and it may not be pathological. Foetal growth restriction (FGR) is a pathological state, based on additional criteria of EBW < 3 rd percentile, poor somatic growth and compensated umbilical/cerebral blood flow.

Placental dysfunction is a major contributing factor to fetal growth restriction. Placenta-mediated fetal growth

restriction occurs through chronic fetal hypoxia owing to poor placental perfusion through a variety of mechanisms. Maternal vascular malperfusion is the most common placental disease contributing to fetal growth restriction. Although the features of maternal vascular malperfusion are identifiable in placental pathology, antepartum diagnostic methods are evolving. Placental imaging and uterine artery Doppler play an increasingly important role.¹

The perinatal outcome of FGR fetuses is largely

Received: 3rd October 2021, Peer review completed: 30th January 2022, Accepted: 6th February 2022.

Sajid E, Ganguli I, Bhalla S, Srivastava M, Dagar M. Histopathological examination of placenta in normal and SGA pregnancy and its association with neonatal outcome. The New Indian Journal of OBGYN. 2023; 10(1): 34 -8.

dependent on the severity of growth restriction with those below the 3rd centile and/or abnormal umbilical artery doppler measurements at greatest risk of adverse outcome.^{2,3}

Although there is no clear evidence of concordance between lesions and clinical disorders, placental pathology can confirm clinical suspicion and provide additional information. It can also be used in medical litigation in cases of adverse neonatal outcomes. The study aimed to evaluate placental pathological findings in pregnancies complicated by FGR and its association with clinical outcome

Materials and methods

This prospective observational study was conducted in the Department of Obstetrics & Gynaecology, Sir Ganga Ram Hospital, New Delhi, India during the period - October 2007 to October 2009.

A total of 100 placentae from pregnancies diagnosed on USG with FGR fetuses were included in the study group and 100 placentae from uncomplicated pregnancies were included in the control group after taking due consent.

Inclusion criteria were: singleton pregnancy, estimated fetal weight (EFW) below the 10th percentile at the routine third-trimester ultrasound examination, and pregnancies with accurate gestational age dating.

Exclusion criteria for the study group include: multiple pregnancies, past/present maternal infection (e.g. malaria, TORCH, tuberculosis, bacterial vaginosis and UTI), acquired thrombophilias, any medical disorder (e.g. maternal hypertensive disorders, sickle cell disease, type II diabetes mellitus, SLE, APLA syndrome and CVS anomalies), extremes of maternal age (<20 and >35 years), extremes of maternal weight (<50kg and >85kg) women with a history of smoking, alcohol or substance abuse, congenital/chromosomal abnormality of fetus.

After delivery, the macroscopic aspect of the placentae was analyzed in the labour room/OT. The placentae were weighed and then sent for histopathological analysis in 10% neutral buffered formalin at room temperature. The following histopathological features of the placentas were systematically assessed: villous infarcts, fetal thrombotic arteriopathy, chronic villitis, perivillous fibrin deposit, decreased vascularity, and diffuse calcification.

Fetal outcomes evaluated include preterm delivery (delivery before 37 weeks gestation), low birth weight (<1500g), low Apgar score (<7 at 5 min) and neonatal death. The establishment of an association between placental

lesions with neonatal outcome was then attempted and results were compiled.

Data were analysed using paired chi-square test between the study and control group. The 'p value' cut off <0.05 was considered statistically significant. Association between individual placental lesions and the neonatal outcome was attempted through paired chi-square test. All analysis was performed via Quickcalcs (Graph Pad Software Inc; San Diego; CA, USA).

Results

After enrolling the patients at the time of delivery a detailed performa was filled for each patient along with the consent form. Patients in the study group were enrolled based on documented ultrasound reports of SGA/FGR fetuses with or without deranged doppler flow.

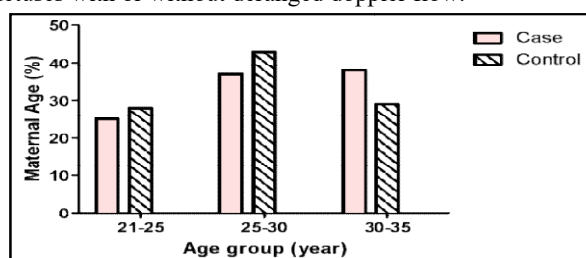


Figure 1: Age distribution

As we had already excluded extremes of age we found the age distribution between the study group and control group almost equivalent (figure 1). Also, we found the majority of females i.e. 54% in the study group primigravida, which shows a stronger correlation of FGR with first pregnancy ($p<0.05$).

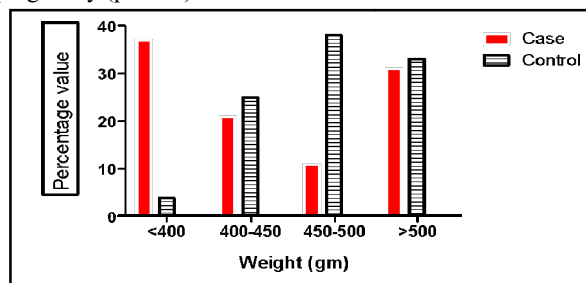


Figure 2: Weight distribution

Since we excluded the extremes of weight we found a comparatively higher distribution of weight in the study group as compared to the control group ($p<0.07$). On studying the weight distribution of the placenta in the study and control group we found that 37% of the placentae of the study group weighed <400 grams which points towards a greater correlation of decreased placental weight with FGR pregnancies. On statistical analysis, we found the

Association between decreased placental weight and FGR statistically significant ($p < 0.01$) (figure 2).

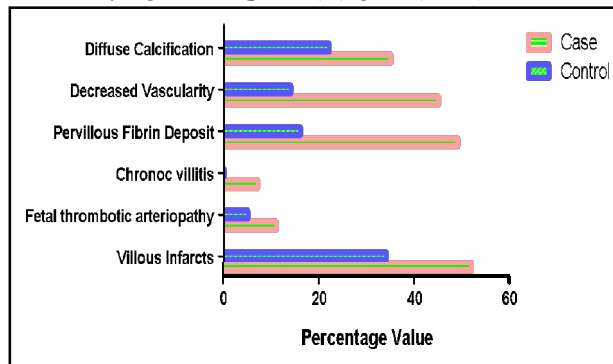


Figure 3: Histopathological findings of placenta

Table 1: Histopathological findings

Histopathology of placenta	Study group	Control group	P value
Villous infarcts	52%	34%	0.015
Fetal thrombotic arteriopathy	11%	5%	0.1913
Chronic villitis	7%	-	0.0140
Perivillous fibrin deposit	49%	16%	0.0001
Decreased vascularity	45%	14%	0.0001
Diffuse calcification	35%	22%	0.0596
Syncytial knots	38%	21%	0.0128

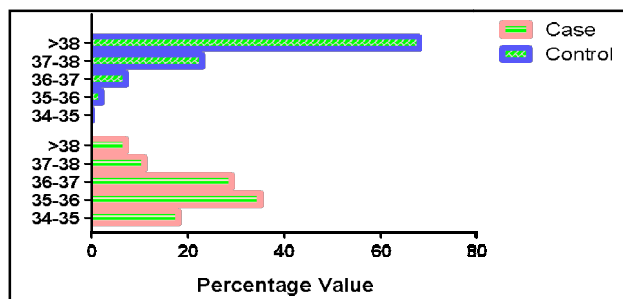


Figure 4: Gestational age during delivery

After a quick survey of delivered placentae, we found that 68% of placentae of the study group exhibited some or

the control group showing a significant association of placental pathology with FGR ($p < 0.05$). Salient histopathological findings in the study group were villous infarcts (52%), fetal thrombotic arteriopathy (11%), chronic villitis (7%), perivillous fibrin deposit (49%), decreased vascularity (45%), diffuse calcification (35%), syncytial knots (38%) (figure 3). The statistical significance in distinguishing placental changes from normal control was evaluated (table 1).

11% of placentae in the study group showed thrombotic arteriopathy compared with 5% in the control group ($p = 0.1913$). A significant number of placentae in the study group showed perivillous fibrin deposition (49%) as compared to the control group (16%) ($p < 0.01$) showing a strong association between this lesion and FGR. Similarly decreased villous vascularity was observed in 45% of women with FGR as compared with only 14% without FGR ($p < 0.01$) which also points towards significant association.

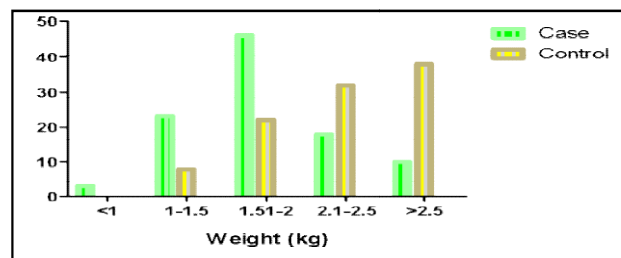


Figure 5: Birth weight

We found that 82% of neonates were delivered before 37 completed weeks in the study group which was a significant finding ($p < 0.01$) (figure 4). This finding could also be attributed to the fact that these pregnancies were already high-risk due to ongoing FGR and this may have prompted early delivery.

The finding of 72% of neonates in the study group with birth weight < 2 kg was expected due to FGR babies. This

Table 2: Relationship between the placental lesion and neonatal outcome depicted at the depression of Apgar score at 5 minute

Placental lesions	Study group	Decreased Apgar score (< 7) at 5 min	P value
Villous infarcts $> 10\%$ area	52%(52/100)	11.1%(1/9)	0.053
Fetal thrombotic arteriopathy	11%(11/100)	0%(0/9)	0.5
Chronic villitis	7%(7/100)	11.1%(1/9)	0.5
Perivillous fibrin deposition	49%(49/100)	11.1%(1/9)	0.037
Decreased vascularity	46%(46/100)	22.2%(2/9)	0.3
Diffused calcification	35%(35/100)	11.1%(1/9)	0.266
Syncytial knots	38%(38/100)	22.2%(2/9)	0.48

the other morphological abnormalities whereas 72% of placentae from the control group were normal morphologically. This difference in computation was statistically significant ($p < 0.01$). On studying the histopathology of the placenta we found abnormalities in 73 % of placentae in the study group as compared to 34% in

finding was statistically significant ($p < 0.01$) (figure 5). We observed that despite preterm delivery the Apgar score at 5min for the study group was > 8 in 62% of neonates suggesting the effect of non-pathological SGA.

We then tried to establish a relationship between individual placental lesions and neonatal outcome (on the

basis of depression of APGAR score at 5 minutes). Our study failed to demonstrate any significant relation between major placental lesions and depression of APGAR score except for perivillous fibrin deposition which showed significant relation ($p<0.05$) (chi-square test) (table 2).

On comparing the placental lesions with decreased fetal weight ($<1.5\text{kg}$) we found decreased vascularity ($p<0.05$)

group while analysing histopathology of the placenta in pregnancies complicated with IUGR.⁴

Another very important lesson to mention was decreased vascularity, which showed a statistically significant difference ($p<0.01$) between the study and control group which was also seen in the study of Barut et al.⁸ Diffuse placental calcification did not show a significant difference

Table 3: Association between placental infarcts and decreased fetal weight

Placenta lesions	Study group	Decreased fetal weight ($<1.5\text{ kg}$)	P value
Villous infarcts	52%(52/100)	34.6%(9/26)	0.2184
Fetal thrombotic arteriopathy	11%(11/100)	7.96%(2/26)	0.4570
Chronic villitis	7%(7/100)	0%(0/26)	0.34
Perivillous fibrin deposition	49%(49/100)	46.1%(12/26)	0.83
Decreased vascularity	46%(46/100)	69.2%(18/26)	0.046
Diffused calcification	35%(35/100)	42.30%(11/26)	0.5
Syncytial knots	38%(38/100)	23.1%(6/26)	0.17

closely related to decreased fetal weight ($p<0.05$). The other lesions failed to show any significant relationship between the two (chi-square two-tailed test) (table 3).

Discussion

In this study, histopathological characteristics of placentae of SGA fetus were studied and an association was formed between neonatal outcome (decrease Apgar score at 5 min) and specific placental lesions.

In our study, we found that the mean distribution of placental weight in the study group was in the lower range when compared with the control group and the distribution of weight in both groups was statistically significant ($p<0.01$). Maria et al also found decreased placental weight distribution in the study group as compared to the control group while studying placenta in pregnancies complicated with FGR.⁴ However, Jako et al (2019) presented research in which the calculated volume of the placenta measured at the time of delivery showed a stronger correlation with birth weight, compared to the association between placental weight and birth weight.⁵

Although placental infarction can be found in both normal and abnormal pregnancies, this lesion presents clinic-morphological significance when it affects at least an average of 10-20% of the placental volume. The relationship between fetal hypoxia, subsequent FGR and the presence of multiple placental infarction lesions has already been reported in the literature.⁶ We found a clinically significant relationship between the occurrence of villous infarcts (10-20%) between the study and the control group.

We found the incidence of perivillous fibrin deposition as statistically significant ($p<0.01$) in the study group as compared to the control group suggesting its strong relation with FGR which was shown in the study of Redline.⁷ Maria et al found perivillous fibrin in 17.46% of cases of the study

between the two groups which is supported by the study by Iskender Mazman et al.⁹

The syncytial knots, which can be used to evaluate villous maturity, have been noted in the placentas of FGR fetuses and are assumed markers of placental ischemia. In the present study, we found statistically significant results while comparing the placentae of FGR fetuses with the control group. Maria et al found an increase in syncytial knots, which were more common in the placentas of SGA fetuses compared to normal placentas (26.69% vs. 9%).⁴

We then tried to establish an association between specific placental lesions and neonatal outcome (decrease Apgar score at 5 min). In our study, we found perivillous fibrin deposition as the only placental lesion which showed significant relation ($p<0.05$) with the adverse neonatal outcome while all other major placental lesions failed to show any significant association. Roy Mondal et al postulated that fetal vasculopathy characterized by increased intra and perivillous fibrinoid, exaggerated syncytial knots, villous fibrosis and fibro muscular sclerosis may be the cause behind chronic placental hypoxia.¹⁰

On establishing an association between placental lesions and decreased fetal weight at birth we found that decreased vascularity is significantly associated ($p<0.05$). The other placental lesions failed to establish any close association between them and decreased fetal weight.

We also tried to find an association between placental lesions and fetal weight (chi-square test) which suggested an association between decreased vascularity ($p<0.05$) and decreased fetal weight. An elaborate study done by Janet et al also found that birth weight was lower among births with malperfusion lesions.¹¹ We still need an elaborate cross-sectional study to firmly establish the relation between

placental lesions and neonatal outcome and specific guidelines to enlist the parameters and methods to compare.

Limitation -The limitation of our study was the presence of many confounding factors in the patients which were difficult to delineate (viz. age, socio-economic background, gestational age on diagnosis and delivery, pre-pregnancy BMI) and the co-occurrence of placental lesions more so in the study group which might have caused a bias in results.

Conclusion

Through our study, we found that though SGA fetuses are more commonly associated with histological placental abnormalities, it cannot be established whether these abnormalities certainly contribute to FGR. Of note are the malperfusion lesions of the placenta which show a close association with not only FGR but decreased fetal weight and poor neonatal outcome which was shown in our study. We also found the association of perivillous fibrin and decreased vascularity significantly related to adverse neonatal outcomes. This suggests that vascular changes in villous structures might be a causal factor for fetal distress and poor neonatal outcome but elaborate cross-sectional studies are needed for further comments.

Conflict of interest: None. **Disclaimer:** Nil.

References

1. Gordijn SJ, Beune IM, Thilanganathan B, Papageorgiou A, et al. The consensus definition of fetal growth restriction: a Delphi procedure. *Ultrasound Obstet Gynecol.* 2016; 48: 333-9.
2. Zur RL, Kingdom JC, Parks WT, Hobson SR. The Placental Basis of Fetal Growth Restriction. *Obstet Gynecol Clin North Am.* 2020; Mar; 47(1): 81-98.
3. Unterscheider J, Daly S, Geary MP, McAuliffe FM, Kennelly MM, Morrison JJ, et al. Optimizing the definition of intrauterine growth restriction—results of the multicenter prospective PORTO study. *AJOG.* 2013, 208(4): 290.e1-6.
4. Maria VN, Mihaela N, Maria MM. Placental findings in pregnancies complicated with IUGR -histopathological and immunohistochemical analysis. *Rom J Morphol Embryol.* 2018; 59(3): 715-20.
5. Jako M, Suranyi A, Kaizer L, Nemeth G, Bartfai G. Maternal haematological parameters and placental and umbilical cord histopathology in intrauterine growth restriction. *Med Princ Pract.* 2019; 28(2):101-8.
6. Gunyeli I, Erdemoglu E, Ceylaner S, Zengeroglu S, Mungan T. Histopathological analysis of the placental lesions in pregnancies complicated with IUGR and stillbirths in comparison with noncomplicated pregnancies. *J Turk Ger Gynecol Assoc.* 2011; 12(2): 75-9.
7. Redline RW. Classification of placental lesions. *Am J Obstet Gynecol.* 2015; 213(4 Suppl): S21-S28.
8. Barut F, Barut A, Gun BD, Kandenir NO, Harma MI, Harma M, et al. Intrauterine growth restriction and placental angiogenesis. *Diagn Pathol.* 2010; 5: 24.
9. Iskender-Mazmam D, Akcoren Z, Yigit S, Kale G, Korkmaz A, Yurdakok M, Durukan T. Placental findings of IUGR and non-IUGR. *Turk J Peiatr.* 2014; 56(4): 368-73.
10. Tanima RM, Gautam B, Sabuj GM, Dyuti G. Histopathological Changes of Placenta in Meconium Stained Liquor and Its Relevance in Fetal Distress. A Case-Control Study. *Turk Patoloji Derg.* 2019, 35: 107-18.
11. Catov JM, Scifres CM, Caritis SN, Bertolet M, Larkin J, Park WT. Neonatal outcomes following preterm birth are classified according to placental features. *Am J Obstet Gynecol.* 2017 Apr; 216(4): 411.e1-411.e14.

Erum Sajid¹, Indrani Ganguli², Sunita Bhalla³, Mala Srivastava⁴, Mamta Dagar⁵

¹ DNB student, Department of Obstetrics and Gynecology, Sir Ganga Ram Hospital, New Delhi, India; ^{2,4,5} Department of Obstetrics and Gynecology, Sir Ganga Ram Hospital, New Delhi, India; ³ Department of Histopathology, Sir Ganga Ram Hospital, New Delhi, India.