DOI - 10.21276/obgyn.2021.8.1.31 *ISSN Print – 2454-2334; ISSN Online – 2454-2342*

CASE REPORT

Acute pyelonephritis in pregnancy - a case report

Anshu Baser, Sunil Sharma, Sushil Kumar

Corresponding author: Dr. Sunil Sharma, Professor, Department of Obstetrics and Gynecology MGM Kalamboli, Sector 4E, Kalamboli Panvel, Navi Mumbai, Maharashtra, India; Email : sunilsharma2860@yahoo.com

Distributed under Attribution-Non Commercial – Share Alike 4.0 International (CC BY-NC-SA 4.0)

ABSTRACT

Acute pyelonephritis is a serious condition which causes significant morbidity in the patient. In pregnancy early diagnosis and appropriate management is essential to prevent both maternal and fetal complications. In this paper we present a report of a case who presented with acute pyelonephritis late in pregnancy. They were started on intravenous antibiotics but did not show an adequate response. On ultrasound the patient had ureteric calculi with upstream pressure changes. DJ stenting was done and the response thereafter was remarkable. The patient recovered and went home with a healthy baby.

Keywords: Pyelonephritis in pregnancy, asymptomatic bacteriuria, DJ stenting in pregnancy.

Urinary symptoms are the most common and most often ignored complications occurring in the antenatal period. Around 2-7% pregnant women experience asymptomatic bacteriuria.[1] If left untreated 20 to 35 % will develop serious urinary tract infections including acute cystitis, acute pyelonephritis.[1] Acute pyelonephritis complicates 2% of pregnancies [2]. It can complicate pregnancies by causing preterm delivery (10%)[3], maternal sepsis, renal failure and respiratory distress leading to significant maternal and fetal morbidity and mortality.[2] Here we present a case report from a tertiary care centre.

Case

Patient Mrs. X, 30 yrs old female gravida 3 para 2, previous both normal deliveries, was admitted at 31 weeks and 2 days gestation with complaints of high grade fever since 3 days associated with chills and rigors. Patient gave a history of burning micturition on and off for 2-3 weeks.

Patient on admission had high grade fever of 103 °F. The patient's basic fever profile which included complete blood counts, peripheral smear for malarial parasite, dengue, widal were unremarkable except that urine routine examination showed increased pus cells (12-15 per high power field). A urine culture was sent and the patient was started on intravenous antibiotics Inj. Ceftriaxone 1gm 12 hourly. Urine culture showed growth of *Escherichia coli* sensitive to ceftriaxone. Patient was monitored for pulse, blood pressure, urine output, fever and uterine contractions. She appeared toxic, had a loss of appetite, and continued to have spikes of fever, chills and rigor. Ultrasound (USG) abdomen and pelvis was done. USG Abdomen and pelvis was suggestive

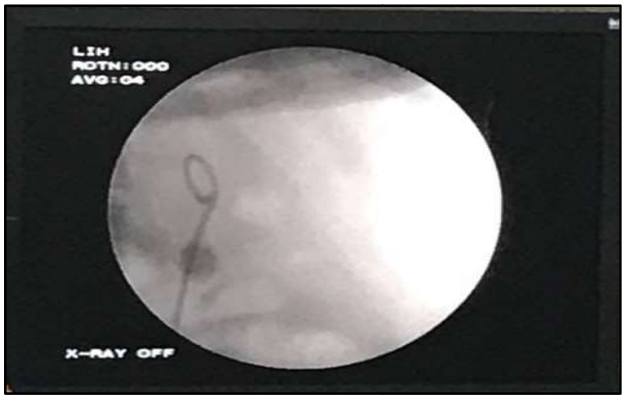

Figure 1: Placement of DJ stent

of 8mm sized renal calculus in the left vesicoureteral junction with evidence of mild upstream hydronephrosis and hydroureter. A urology opinion was taken and a diagnosis of

Received: 9th July 2020, Peer review completed: 12th August 2020, Accepted: 28th January 2021.

Baser A, Sharma S, Kumar S. Acute pyelonephritis in pregnancy - a case report. The New Indian Journal of OBGYN. 2021; 8(1): 152-54.

acute pyelonephritis with sepsis was made. The patient underwent DJ stenting (figure 1 and 2) and subsequently the patient's fever spikes reduced.

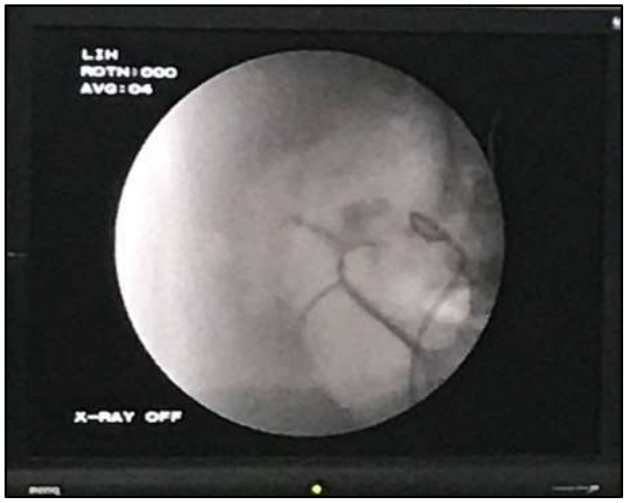

Figure 2: Placement confirmed by dye injection

The patient was discharged once there was no fever for 48 hours and asked to follow up regularly. There was no relapse of febrile illness. The patient delivered a healthy female baby of 2.5 kg at term and post delivery the DJ stent was removed.

Discussion

Acute pyelonephritis usually presents with high grade fever (temperature ≥ 38°C), flank pain, costovertebral angle tenderness and tachypnea. Other common symptoms include nausea, vomiting and chills with rigor. Acute pyelonephritis is mainly a clinical diagnosis however in non resolving cases ultrasound and other imaging modalities may be used. However a negative ultrasound KUB does not rule out the diagnosis.[4,5] Laboratory findings of bacteriuria (20 bacteria per high-power field), pyuria, increase total leukocyte counts and raised serum creatinine are usually present. Urinary dipstick testing for leukocyte esterase and nitrites is often positive [4], electrolyte abnormalities and raised serum lactate dehydrogenase levels may also be present.

Acute pyelonephritis is normally categorised as complicated and uncomplicated. In pregnancy however any degree of pyelonephritis is considered complicated.[5] It can occur by hematogenous route or by ascending urinary tract infection the latter being more common.[6] The most common pathogen was reported to be *Escherichia coli* accounting for around 80% of cases. Other pathogens implicated are normal perineal flora like *Klebsiella, Proteus* and coagulase negative *Staphylococcus*[4]. The Infectious Diseases Society of America (IDSA) has also defined that asymptomatic bacteriuria (greater than 100,000 cfu/mL) if left untreated, can lead to up to 40% of cases of pyelonephritis.[5] Urinary tract obstruction caused by something such as a kidney stone can also lead to acute pyelonephritis. Physiologic and anatomic changes that occur as a result of the gravid state predispose women to urinary tract infection (UTI) in general. These include: [4]

- Progesterone induces relaxation of the smooth muscles of renal calyces and ureters, causing dilatation and stasis which promotes bacterial growth.
- The growing uterus causes a mechanical compression on the ureters, particularly on the right.
- Mechanical compression of the bladder and relaxation in detrusor muscle tone, leading to post-void residual urine volume, contribute to higher propensity for UTI in pregnancy.
- Glucosuria in cases of gestational diabetes mellitus and alkalinization of the urine also increases the risk for UTI.

Pyelonephritis most commonly occurs during the second trimester. The mechanical compression by the uterus most often cause urinary stasis in the right ureter and hence pyelonephritis most commonly occurs in the right kidney.[6,7] The mainstay of treatment of acute pyelonephritis is hospitalization, intravenous antibiotics, hydration and antipyretics. Choice of antimicrobial therapy depends on the trimester, urine culture sensitivity and antimicrobial resistance patterns prevailing in the hospital. Maternal-fetal morbidity does not differ significantly between first, second or third trimesters but first trimester acute pyelonephritis should be treated early and aggressively to prevent maternal-fetal compromise.[4] Acute pyelonephritis can lead to serious maternal and fetal morbidity and mortality. The most common complications associated are preterm delivery [4], anemia (approximately 25% of patients) and bacteremia (15-20% of cases). Urosepsis, septic shock, respiratory insufficiency (2-8%) and disseminated intravascular coagulation (DIC) are potentially fatal complications that may result from bacteremia.

Role of DJ stenting: Oral/ intravenous antibiotics are the mainstay of treatment of acute pyelonephritis however diversion procedures may be considered in the presence of two or more of the following conditions: [8]

- Gross pyuria,
- Significant fever spikes despite medication,
- Persistent loin tenderness,

- Persistently high total count despite medication
- Persistently high serum creatinine,
- Thrombocytopenia,
- Positive blood or urine culture and HbA1c > 9.2%.
- Urinary calculi causing obstruction.

In a typical DJ stenting the X-ray exposure is 10-50 mGy which is well within the guidelines of 0.1 Gy given by CDC.[9]

Conclusion

The aim of this publication was to make the clinician aware of the presentation and management of acute pyelonephritis in pregnancy. In pregnant women asymptomatic bacteriuria, if left untreated can lead to acute pyelonephritis and other serious urinary tract problems in as high as 20-35% cases. Apart from asymptomatic bacteriuria patients' with recurrent urinary tract infections and gestational or overt diabetes are also at a high risk of developing complications such as acute cystitis, acute pyelonephritis. The role of the obstetrician here lies in identifying high risk cases by routine antenatal screening followed by appropriate management. Awareness of the presentation of acute pyelonephritis and other serious urinary tract ailments can lead to their early management and prevent life threatening complications.

Acknowledgements -

I would like to thank my mother, Dr. Archana Baser, for her constant guidance and persuasion, my father Dr. Brajendra Baser for his advice, Dr. Sunil Sharma who was both co-author and guide for this article and my co-residents for tolerating my never ending questions. Would also like to thank the urology department for their joint management of these cases.

Conflict of interest: None. **Disclaimer:** Nil.

References

1. Cunningham FG, Leven KJ, Bloom SL, Spong CY, Dashe JS, Hoffman BL, et al. Renal and Urinary Tract Disorders. William's Obstetrics. 24th ed. New York: McGraw-Hill Education; 2014. p. 1053-57.
2. Patterson TF, Andriole VT. Detection, significance, and therapy of bacteriuria in pregnancy. Infect Dis Clin North Am. 1997 Sep;11(3):593-608..
3. Wing DA, Fassett MJ, Getahun D. Acute pyelonephritis in pregnancy: an 18-year retrospective analysis. American Journal of Obstetrics and Gynecology. 2014; 210(3): e1-e6.
4. Benson RC, Mitchell JC. Urinary tract infections in pregnancy. Clin Obstet Gynecol. 1958; 1(1): 97-118.
5. Nicolle L, Gupta K, Bradley S, Colgan R, Muri G, Drekonja D, et al. Clinical Practice Guideline for the Management of Asymptomatic Bacteriuria: 2019 Update by the Infectious Diseases Society of America. Clin Infect Dis. 2019 May 2; 68(10): e83-e110..
6. Dawkins JC, Fletcher HM, Rattray CA, Reid M, Gordon-Strachan G. Acute Pyelonephritis in Pregnancy: A Retrospective Descriptive Hospital Based-Stud. Obstetrics and Gynecology. 2012; 2012; 1-6.
7. Saleh P, Noshad H, Mallah F, Ramouz A. Acute Pyelonephritis in Pregnancy and the Outcomes in Pregnant Patients. Arch Clin Infect Dis. 2015;10(3): e28886
8. Kumar SB, Palaniyandi V, Krishnamoorthy S, Ramanan V, Kumaresan N. Role of Minimally Invasive Urological Intervention in Acute Pyelonephritis. International Journal of Scientific Study. 2018; 5(12): 114-19.
9. Shaw P, Duncan A, Vouyouka A, Ozsvath K. Radiation exposure and pregnancy. Journal of Vascular Surgery. 2011; 53(1): 28–34.

Anshu Baser [1], Sunil Sharma [2], Sushil Kumar [3]

[1] Junior Resident, Department of Obstetrics and Gynaecology, MGM Medical College, Navi Mumbai, Maharashtra, India; [2] Professor, Department of Obstetrics and Gynaecology, MGM Medical College, Navi Mumbai, Maharashtra, India; [3] Professor & HOD, Department of Obstetrics and Gynaecology, MGM Medical College, Navi Mumbai, Maharashtra, India.